

The frequency of occurrence of different types of hpv and the possible risk of developing cervical cancer in women aged 19-45 years (on the example of the Kirov region)

Milchakov Dmitry Evgenievich

Candidate of Medical Sciences, Associate Professor

Rodygina Sofia Michailovna

Student

Kirov State Medical University

Tsurkan Yulia Andreevna

Student

Kirov State Medical University

Abstract. This article examines the impact of human papillomavirus types 16 and 18 on the risk and rate of development of cervical cancer in women aged 19-45 years living in the Kirov region. The effectiveness of radical treatment in women with severe cervical dysplasia was evaluated. Surgical treatment consisted of elektroconization of the cervix, followed by histological examination of the biological material.

Keywords: Human papillomavirus (HPV), elektroconization, dysceratosis, coilocytes, L-SIL, H-SIL, cervical dysplasia.

Introduction

Human papillomavirus (HPV) is a DNA virus of the Papovaviridae family. They are a widespread and highly variable group of viruses with oncogenic potential.

In clinical practice, in terms of their transforming activity with respect to epithelial cells, all known papillomaviruses are divided into two main groups¹: papillomaviruses of low oncogenic risk (mainly HPV 1, 2, 3, 5, 6, 11, 30, 40, 42, 43, 44, 53, 61) and papillomaviruses of high oncogenic risk (HPV 16, 18, 31, 33, 35, 39, 45, 51, 52, 56, 58, 59, 68). The list of HPV types of high oncogenic risk is expanding due to the clarification of the DNA structure and the emergence of new types of intermediate risk. The rest of the types are not included in the classification, since their explicit belonging to one of these groups is not clearly traced.

HPV is spread by close contact with infected or diseased epithelium. The target cells for HPV are epithelial cells of the skin and mucous membranes.

When it enters the body, the human papillomavirus infects the basal layer of the epithelium. The target for the impact of oncogenic HPV types is the transformation zone of the

¹ Dillner J., Meijer C.J., von Krogh G., Horenblas S. Epidemiology of human papillomavirus infection // Scand. J. Urol. Nephrol. Suppl. 2000; (205):194–200.

cervix, where precancerous changes in the cervix develop. In this area, cells of the basal layer of the epithelium that are sensitive to HPV infection are located closest to the surface and favorable conditions are created for HPV infection.

The HPV infection rate reflects in one way or another the incidence of HPV-related diseases. It has been shown that the incidence of cervical cancer depends on sexual behavior, and the risk of HPV infection depends on the age of sexual debut, the number of sexual partners, the method of contraception, the presence of concomitant infections and diseases of the urogenital tract. So, according to the WHO, about 600 thousand cases of cervical cancer are recorded in the world every year. Despite the ongoing therapy, 45–55% of patients have an unfavorable outcome².

Cervical cancer is a severe, rapidly progressive and intractable disease that affects women of childbearing and working age. Despite the effective arsenal of surgical, radiation and chemotherapeutic agents for the treatment of cervical cancer, used as independent and complex methods, mortality from malignant tumors of the genital organs in women remains high. One-year mortality from the moment of diagnosis for cervical cancer is 16,3 %³.

The course of HPV infection is quite variable: it can spontaneously regress, persist and recur (progress with the development of CIN), and, accordingly, is characterized by different visual and colposcopic picture, as well as various morphological signs⁴.

With the references⁵, the most specific cells for HPV infection are koilocytes. These cells are formed due to the cytopathic action of HPV and are cells of the stratified squamous epithelium of the intermediate type with enlarged nuclei, an uneven folded membrane and hyperchromatosis. Cytoplasm is stored only in the peripheral portion of the cells, forming perinuclear halo (perinuclear bleaching zone is formed due to degenerative changes and necrosis the cytoplasmic organelles destroyed).

² Fighting major diseases in Europe-current problems and ways to solve them // Facts and Figures of the WHO Regional Office for Europe Copenhagen [Electronic resource]. 2006. Access mode: <http://www.euro.who.int/mediacentre>.

³ Methodology of screening of precancerous diseases and tumors of the cervix, uterus and ovaries: Instructions for use, approved by the Ministry of Health of the Russian Federation. M-vom Healthcare Rep. Belarus 3.02.2005. /I. V. Zalutsky [et al.]. Minsk: Dikta, 2005. 3 p

⁴ Semenov D. M. Clinical and pathogenetic aspects of papillomavirus infection in obstetric and gynecological practice: Sb. nauchn. tr. VSMU. Vitebsk, 2004.

⁵ Rogovskaya S. I. Papillomavirus infection in women and pathology of the cervix. Moscow: GEOTAR-Media 2005. pp. 48-67. 7.

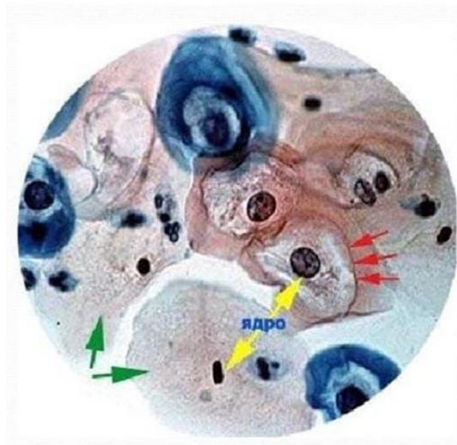


Image 1. Koilocytic atypia

The second most specific cell in HPV infection is dyskeratocyte. Dyskeratocytes are small cells of stratified squamous epithelium with pyknotic nuclei of various shapes and sizes and intense eosinophilic cytoplasm, which are located in complexes in the surface layers of the epithelium.

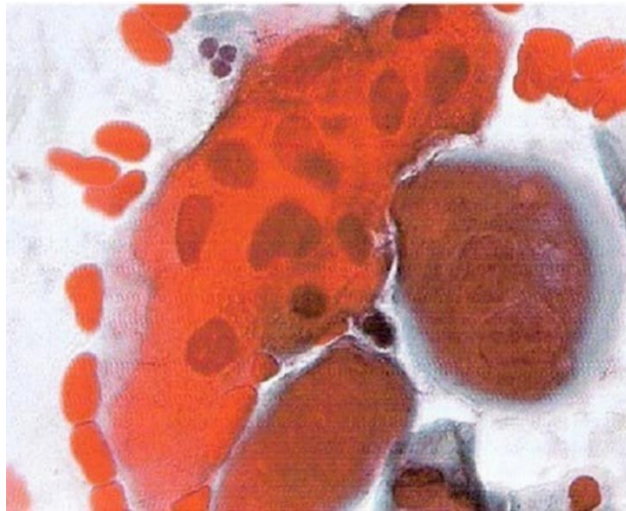


Image 2. Dyskeratosis

Currently, there is no doubt that there is a direct link between the detection of highly oncogenic HPV types in the cervical tissues and a higher severity of CIN. Thus, detection of HPV DNA with CIN and cervix cancer, detection koilocytes, specific cytopathic action HPV, can be attributed to a pathological condition of HPV-associated diseases.

In the diagnosis of HPV-associated diseases, various methods are used, such as:

- clinical and visual;
- colposcopic;
- cytological;
- histological;
- immunocytochemical for the detection of HPV capsid antigen;

- electron microscopic for finding mature virions in cells;
- computed resonance imaging;
- ultrasound examination (ultrasound); and others⁶.

To search for prognostic signs of cell proliferation with an unfavorable prognosis even at the stage of early cellular changes, when colposcopy and cytological examination are not effective enough, ways of improving the method of cytological examination of the cervix are proposed:

1. standardized sampling of cellular material from the surface of the cervix, the transformation zone and from the cervical canal;

2. application of the liquid cytology technique for the preparation of a cytological preparation;

3. Subsequent immunocytochemical study, determination of p16ink4 α protein expression in dysplastic cells. The technique of liquid cytology (LC), a new technology for the preparation of cytological preparations, is increasingly used in clinical practice.

In accordance with European recommendations and the opinion of WHO 2005 experts, life cycle improves the quality of samples and is a more sensitive method with identical specificity compared to traditional cytological examination. The indisputable advantage of the technique is that the sample can be used for molecular research, for example, for the immunocytochemical determination of the p16 protein (INK4 α).

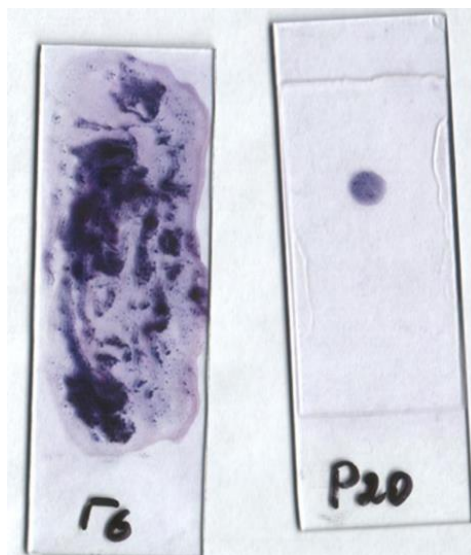


Image 3. Cytological specimen of standard cytological examination (left) monolayer specimen formed by the method of liquid cytology (right)

⁶ Batkaev E. A., Kitsak V. Ya., Korsunskaya I. M., Lipova E. V. Viral diseases of the skin and mucous membranes: Textbook. Manual. Moscow, 2001.

Solid line: delineates the area of the cervix. Dotted line: Original squamous junction, outer border of the transformation zone. Dotted line: Current squamous junction, represents the border between columnar epithelium and metaplastic squamous epithelium in the transformation zone.

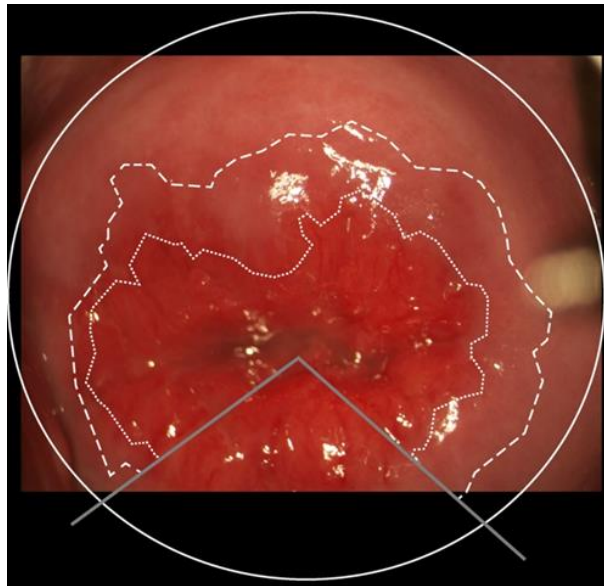


Image 4. Fotokolposkopic image of the ektocervix, having the features of tumor transformation

According to the literature, modern methods of treatment are mainly aimed at removing lesions caused by HPV by physical methods, but these effects often do not provide for a systemic antiviral effect on the intracellular mechanisms of viral replication, which can cause the onset of a relapse of the disease in a short time after removal of the primary pathological focus.

Conization of the cervix includes the removal of the conical portion of the cervical tissue. The base of the cone is formed by the tissues of the exocervix (the vaginal part of the cervix), and the top is formed by the t canal of the cervical canal. Zone transformation (the boundary between exo- and endocervix) is included in a conical tissue specimen. With histological confirmation of the diagnosis, the absence of tumor cells in the margins of resection and scraping from the cervical canal, the reduced volume of surgical intervention is considered adequate (I, A). Loop elektroconization of the cervix or a LEEP (the Loop Electrosurgical Excision Procedure) or LLEETZ (Large the Loop Electrosurgical Excision of Transformation Zone - big loop electrosurgical loop first excision of the transformation zone). The LEEP procedure is a surgical procedure that involves the excision of a thin layer of abnormal tissue using an electric current through thin electrodes. The obtained tissue sample is sent to the laboratory for research.

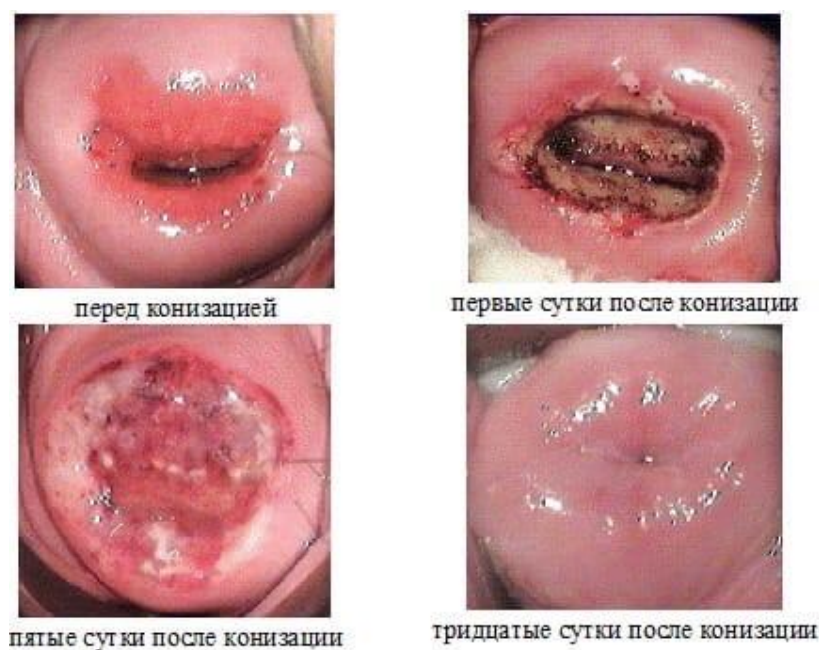


Image 5. Colposcopic picture of the cervix after electroconization

Blocking the main mechanisms of carcinogenesis is a new approach to the prevention of recurrence of CIN associated with HPV. A chemical compound with anti-cancer properties - indole-3-carbinol (I3C), the drug Indinol, blocks the synthesis of the viral oncoprotein E7, prevents the formation of "aggressive" 16 α -hydroxyestrone, and causes selective apoptosis of virus-infected cells. The flavonoid epigallocatechin -3-gallate (EGCG) directionally regulates the activity of tumor suppressor genes (their reversible genetic abnormalities, the so-called epigenetic modifications, are an effective inhibitor of DNA methyltransferase). DNA methyltransferase is an enzyme, the increase of which is noted with increased tumor-forming activity of cells resulting from methylation of antitumor defense genes. The process of gene methylation is not a true mutation; it is a reversible process. The flavonoid epigallocatechin -3-gallate (EGCG), suppressing the activity of DNA methyltransferase, demethylates "silent" (transcriptionally inactive) genes involved in the process of carcinogenesis: tumor suppressor gene p16 (INK4 α), gene for retinoid and other receptors (RAR). compounds I3C and EGCG, presented in the drug Promisan, is effective in preventing recurrence of CIN, since in this case not only a targeted effect on the pathogenetic mechanisms of HPV development is carried out, but also targeted activation of the expression of tumor suppressor genes that provide antitumor protection of the body⁷.

⁷ Cervical dysplasia-etiopathogenesis, diagnosis, optimal treatment tactics A. E. Protasova, T. I. Dzyubiy, G. A. Raskin, N. I. Tapilskaya, I. E. Zazerskaya, E. D. Khadzheva Textbook. - St. Petersburg: 2014. - 22 p.

Purpose of the study- to establish the impact of 16 and 18 types of HPV on the severity of cervical dysplasia in women aged 19-45 years living in the Kirov region, as well as an assessment of the effectiveness of radical treatment.

Materials and methods

Using the statistical and analytical method, we analyzed 42 medical records of women living in the Kirov region for the period from 2016 to 2021.

Results and discussion

This study included an analysis of the statistics on the incidence of women with cervical dysplasia of varying severity. One of the fundamental factors in the development of cervical dysplasia is the presence of HPV of high carcinogenic risk - 16 and 18. Of the 42 medical records examined, 32 women (76%) were carriers of HPV type 16, and 10 women (24%) were carriers of HPV type 18. The data are clearly shown on the chart 1.

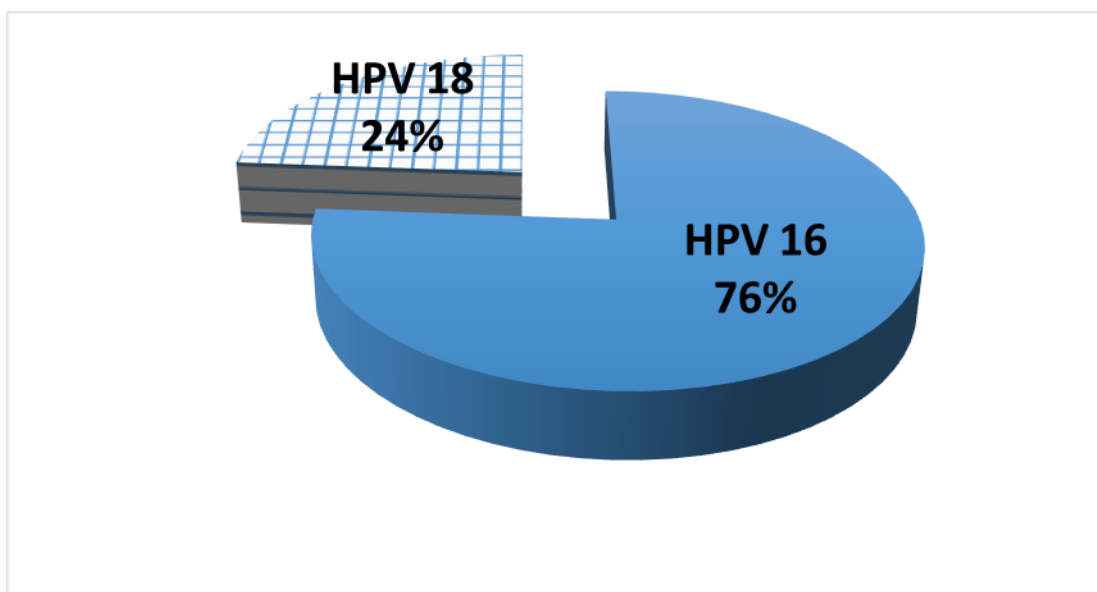
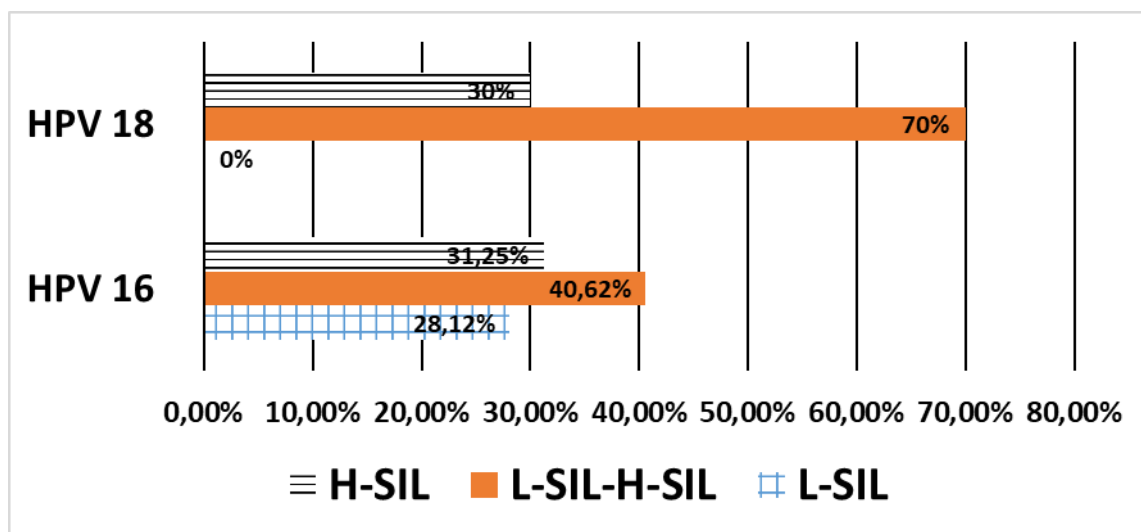


Chart 1. Percentage of women carriers of HPV types 16 and 18

There is a modern classification of the severity of the course of cervical dysplasia. L-SIL (Low grade Squamous Intraepithelial Lesions, cervical intraepithelial neoplasia I, CIN I) and H-SIL (moderate neoplasia of the cervix-High grade Squamous Intraepithelial Lesions, CIN-II) are distinguished. Based on this classification, summary charts were compiled showing the percentage of women with type 16 HPV and type 18 HPV, which include both the presence of L-SIL and the transition from L-SIL to H-SIL, and H-SIL. Among women suffering from 16 types of HPP, L-SIL was observed in 9 women (28.12%) out of 32, the transition from L-SIL to H-SIL - in 13 women (40.62%), H-SIL - in 10 women (31.25%).

Among women with 18 types of HPV, L-SIL was 0%, the transition from L-SIL to H-SIL was observed in 7 women (70%), H-SIL - in 3 women (30%). The data is shown on the graph 2.



Graph 2. Dynamics of the severity of cervical dysplasia in different types of HPV

For both L-SIL and H-SIL, drug treatment was mandatory. With a severe severity of dysplasia, electroconization of the cervix is strongly recommended. In total, there were 33 (78.5% of the total) women with the final H-SIL form from both groups. 30 (90%) of 33 women underwent electroconization of the cervix, 3 (10%) of 33 women have not followed the recommendations at the moment, since they are on sick leave with ARVI.

Positive dynamics after electroconization was observed in 20 (67%) of 30 women: the absence of HPV and pathologies according to the results of oncocytology for several months. Ten women (33%) had a minimal response to treatment. The data are presented on the chart 3.

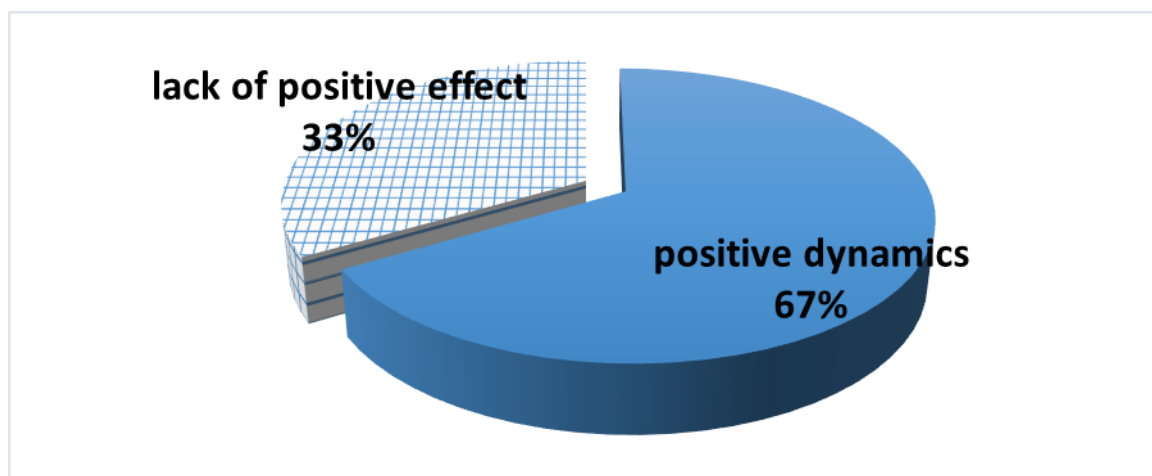


Chart 3. Evaluation of the effectiveness of radical treatment

Conclusion

During colposcopy, all 42 women had atypical transformation zones with varying degrees of severity depending on the HPV type. Based on the analysis of women's medical records, it was revealed that 76% of women had HPV the type of 16, and 24% were carriers of HPV the type of 18. In parallel, it was revealed that a mild severity of dysplasia (L-SIL) was observed with HPV the type of 16 in a percentage equivalent of 28.12%, while with HPV the type of 18 this indicator was 0%. When analyzing the data obtained in the study of the percentage of the transition of L-SIL to the H-SIL form, there was a significant increase in this indicator among HPV the type of 18. Severe dysplasia was observed in both HPV the type of 16 and HPV the type of 18 in equal measure.

According to the results of the study, the method of electroconization was chosen as a radical treatment for HPV of severe severity of cervical dysplasia. Of the people who underwent the procedure, significant improvements were observed in 67% of women.

It is worth noting that the success in the treatment of cervical dysplasia depends not only on the tactics of the specialist's management of the patient with this pathology, but also on the woman's conscious understanding of the severity and consequences that may occur with an unfair approach to the doctor's recommendations.

References

1. Batkaev E.A., Kitsak V.Ya., Korsunskaya I.M., Lipova E.V. Viral diseases of the skin and mucous membranes: Textbook. Benefit. M., 2001.
2. Bashmakova MA, Savicheva AM Human papillomaviruses and their role in tumor formation // M.: Med.; N. Novgorod, 1999. 16 p.
3. The fight against major diseases in Europe - topical problems and ways to solve them // Facts and figures of the WHO Regional Office for Europe Copenhagen [Electronic resource]. 2006. Available at: <http://www.euro.who.int/mediacentre>.
4. Bokhman Ya.V. Guidance on gynecological oncology. L.: Medicine, 1989. S. 195-199.
5. Dysplasia of the cervix - etiopathogenesis, diagnosis, optimal treatment tactics A.E. Protasova, T.I. Dzyubiy, G.A. Raskin, N.I. Tapil'skaya, I.E. Zazerskaya, E. D. Khadzhieva Study guide. - SPb.: 2014. — 22 p.
6. Methodology for screening precancerous diseases and tumors of the cervix, uterine body and ovaries: Instructions for use, approved. Ministry of Healthcare Resp. Belarus 3.02.2005. / I.V. Zalutsky [and others]. Minsk: Dikta, 2005.3 p.
7. Rogovskaya S.I. Human papillomavirus infection in women and cervical pathology. M.: GEOTAR - Media 2005. P. 48–67.
8. Semenov D.M. Clinical and pathogenetic aspects of human papillomavirus infection in obstetric and gynecological practice: Sat. scientific. tr. VSMU. Vitebsk, 2004.
9. Dillner J., Meijer C. J., von Krogh G., Horenblas S. Epidemiology of human papillomavirus infection // Scand. J. Urol. Nephrol. Suppl. 2000; (205): 194-200.
10. Sigve Holmen Female genital schistosomiasis and reproductive tract infections. A cross-sectional study in rural adolescents in South Africa 2019.